





Clinical management of chronic mesenteric ischemia

Louisa JD van Dijk^{1,2} , Desirée van Noord^{1,3}, Annemarie C de Vries¹, Jeroen J Kolkman^{4,5}, Robert H Geelkerken^{6,7} , Hence JM Verhagen⁸, Adriaan Moelker² and Marco J Bruno¹; on behalf of the Dutch Mesenteric Ischemia Study group

Abstract

This review provides an overview on the clinical management of chronic mesenteric ischemia (CMI). CMI is defined as insufficient blood supply to the gastrointestinal tract, most often caused by atherosclerotic stenosis of one or more mesenteric arteries. Patients classically present with postprandial abdominal pain and weight loss. However, patients may present with, atypically, symptoms such as abdominal discomfort, nausea, vomiting, diarrhea or constipation. Early consideration and diagnosis of CMI is important to timely treat, to improve quality of life and to prevent acute-on-chronic mesenteric ischemia. The diagnosis of CMI is based on the triad of clinical symptoms, radiological evaluation of the mesenteric vasculature and if available, functional assessment of mucosal ischemia. Multidisciplinary consensus on the diagnosis of CMI is of paramount importance to adequately select patients for treatment. Patients with a consensus diagnosis of single-vessel or multi-vessel atherosclerotic CMI are preferably treated with endovascular revascularization.

Keywords

Chronic mesenteric ischemia, atherosclerosis, median arcuate ligament syndrome, computed tomography angiography, endovascular therapy

Received: 12 September 2018; accepted: 15 November 2018

Introduction

Chronic mesenteric ischemia (CMI) requires timely diagnosis and treatment to prevent the development of acute mesenteric ischemia, which is associated with high morbidity and mortality. CMI is a diagnosis that is difficult to establish as symptoms are highly variable

This Dutch Mesenteric Ischemia Study group consists of:

Ron Balm, Academic Medical Center, Amsterdam
Gert Jan de Borst, University Medical Center Utrecht, Utrecht
Juliette T Blauw, Medisch Spectrum Twente, Enschede
Marco J Bruno, Erasmus MC University Medical Center, Rotterdam
Olaf J Bakker, St Antonius Hospital, Nieuwegein
Louisa JD van Dijk, Erasmus MC University Medical Center, Rotterdam
Hessel CJL Buscher, Gelre Hospitals, Apeldoorn
Bram Fioole, Maasstad Hospital, Rotterdam
Robert H Geelkerken, Medisch Spectrum Twente, Enschede
Jaap F Hamming, Leiden University Medical Center, Leiden
Jihan Harki, Erasmus MC University Medical Center, Rotterdam
Daniel AF van den Heuvel, St Antonius Hospital, Nieuwegein
Eline S van Hattum, University Medical Center Utrecht, Utrecht
Jan Willem Hinnen, Jeroen Bosch Hospital, 's-Hertogenbosch
Jeroen J Kolkman, Medisch Spectrum Twente, Enschede
Maarten J van der Laan, University Medical Center Groningen, Groningen
Kaatje Lenaerts, Maastricht University Medical Center, Maastricht
Adriaan Moelker, Erasmus MC University Medical Center, Rotterdam
Desirée van Noord, Franciscus Gasthuis & Vlietland, Rotterdam
Maikel P Peppelenbosch, Erasmus MC University Medical Center, Rotterdam
André S van Petersen, Bernhoven Hospital, Uden
Pepijn Rijnja, Medisch Spectrum Twente, Enschede
Peter J van der Schaar, St Antonius Hospital, Nieuwegein
Luke G Terlouw, Erasmus MC University Medical Center, Rotterdam
Hence JM Verhagen, Erasmus MC University Medical Center, Rotterdam
Jean Paul PM de Vries, University Medical Center Groningen, Groningen
Dammis Vroegindewij, Maasstad Hospital, Rotterdam

¹Department of Gastroenterology and Hepatology, Erasmus MC University Medical Center, Rotterdam, the Netherlands

²Department of Radiology, Erasmus MC University Medical Center, Rotterdam, the Netherlands

³Department of Gastroenterology and Hepatology, Franciscus Gasthuis & Vlietland, Rotterdam, the Netherlands

⁴Department of Gastroenterology and Hepatology, Medisch Spectrum Twente, Enschede, the Netherlands

⁵Department of Gastroenterology and Hepatology, University Medical Center Groningen, Groningen, the Netherlands

⁶Department of Vascular Surgery, Medisch Spectrum Twente, Enschede, the Netherlands

⁷Technical Medical Center, Faculty Science and Technology, University Twente, Enschede, the Netherlands

⁸Department of Vascular Surgery, Erasmus MC University Medical Center, Rotterdam, the Netherlands

Corresponding author:

Louisa JD van Dijk, Department of Gastroenterology and Hepatology and Department of Radiology, Erasmus MC University Medical Center, 's-Gravendijkwal 230, 3015 CE Rotterdam, The Netherlands.
Email: l.vandijk@erasmusmc.nl

and diagnostic tests may be inconclusive. Recently, three guidelines for CMI management have been published: a clinical practice guideline of the European Society of Vascular Surgery (ESVS),¹ criteria on radiological management by the American College of Radiology (ACR)² and quality improvement guidelines for endovascular revascularization by the Society of Interventional Radiology (SIR).³ Gastroenterology guidelines on CMI are lacking. This review provides an overview of available literature on the clinical management of patients suspected of CMI with focus on occlusive arterial CMI.

Clinical presentation

CMI is defined as insufficient blood supply to the gastrointestinal (GI) tract resulting in ischemic symptoms with duration of at least three months.¹ Typical symptoms of CMI include postprandial abdominal pain with food aversion and weight loss. The abdominal pain is classically located in the mid-abdomen or epigastrium and starts usually 20–30 minutes after a meal with a duration of 1–2 hours. Atypical symptoms are constant abdominal discomfort, nausea, vomiting, diarrhea or constipation.¹ Abdominal bruit may be present during physical examination; however, the “classic CMI triad” of postprandial abdominal pain, weight loss and abdominal bruit is only present in 16–22% of CMI patients.^{4,5}

Etiology

Atherosclerotic stenosis of one or more mesenteric arteries is the cause in >90% of CMI cases.⁶ Less frequently CMI is caused by vasculitis. Three mesenteric arteries provide blood supply to the intestines: the celiac artery (CA), superior mesenteric artery (SMA) and inferior mesenteric artery (IMA). An extensive collateral circulation exists between these arteries. Asymptomatic mesenteric stenoses are common in the general population and prevalence increases with age. The prevalence of asymptomatic CA and/or SMA stenosis is reported as 3% in patients under 65 years and 18% in patients older than 65 years.⁷

Multi-vessel mesenteric stenosis causing CMI is a well-accepted conception, whereas insufficient blood supply caused by isolated mesenteric stenosis is thought to be limited because of abundant collaterals. If the collateral circulation is insufficient, however, revascularization of a single-vessel stenosis will result in symptom relief.^{5,8–10}

The most common cause of isolated CA stenosis is median arcuate ligament syndrome (MALS): anatomical eccentric compression of the CA and/or celiac ganglion by the median arcuate ligament (MAL) and

diaphragmatic crura.¹¹ The degree of stenosis caused by the MAL depends on the respiratory cycle. The MAL moves caudally during inspiration, releasing the compression on the CA and increasing compression during expiration (Figure 1), although compression only during inspiration may be observed as well. Characteristics of patients with CMI differ depending upon the underlying cause being MALS or atherosclerosis (Table 1).^{12–18}

Chronic non-occlusive ischemia (NOMI) or “migraine abdominale”¹⁹ is characterized by symptoms of CMI in the absence of a vascular stenosis and is diagnosed in up to 13–16% of all CMI patients.¹⁰ Several pathophysiological mechanisms causing chronic NOMI have been suggested: underlying conditions such as cardiac and pulmonic insufficiency, shunts, occlusion of smaller arteries due to spasms or micro-emboli, and autonomic dysfunction. Therapy is directed to ameliorate the adverse effects of the underlying pathophysiological mechanism that is vasodilating medication in case of autonomic dysfunction or optimizing oxygen supply to the GI tract in case of underlying cardiac or pulmonic disease. Successful treatment of these patients, however, is challenging because the etiology of chronic NOMI is not fully unraveled yet.

Diagnosis

In the absence of a golden standard test, the diagnosis of CMI is established by consensus in a multidisciplinary meeting attended by vascular surgeons, gastroenterologists and (interventional) radiologists.^{1,20} The consensus diagnosis is based on clinical symptoms, radiological evaluation of the mesenteric vasculature and, if available, functional assessment of mucosal ischemia.^{21–23} The value of symptoms alone is limited for the prediction of the diagnosis of CMI.^{4,24,25}

Computed tomography angiography (CTA) is the primary imaging modality in patients with a moderate or high suspicion of CMI to assess the mesenteric arteries and to detect other intra-abdominal pathology according to the ESVS guidelines.¹ CTA depicts various atherosclerotic plaque components such as soft plaque and calcifications with a sensitivity for mesenteric artery stenosis of 100% and a specificity of 95%.²⁶ Current magnetic resonance angiography (MRA) techniques seem not as accurate as CTA, especially for the IMA and smaller branch vessels.²⁷ When CTA is not feasible, that is in the presence of contrast allergy or renal insufficiency, MRA can be used as an alternative according to the ACR guidelines.² Duplex ultrasound (DUS) can be used as first screening imaging modality to identify a mesenteric artery stenosis. DUS identifies a $\geq 70\%$ CA stenosis with a sensitivity of 72–100% and

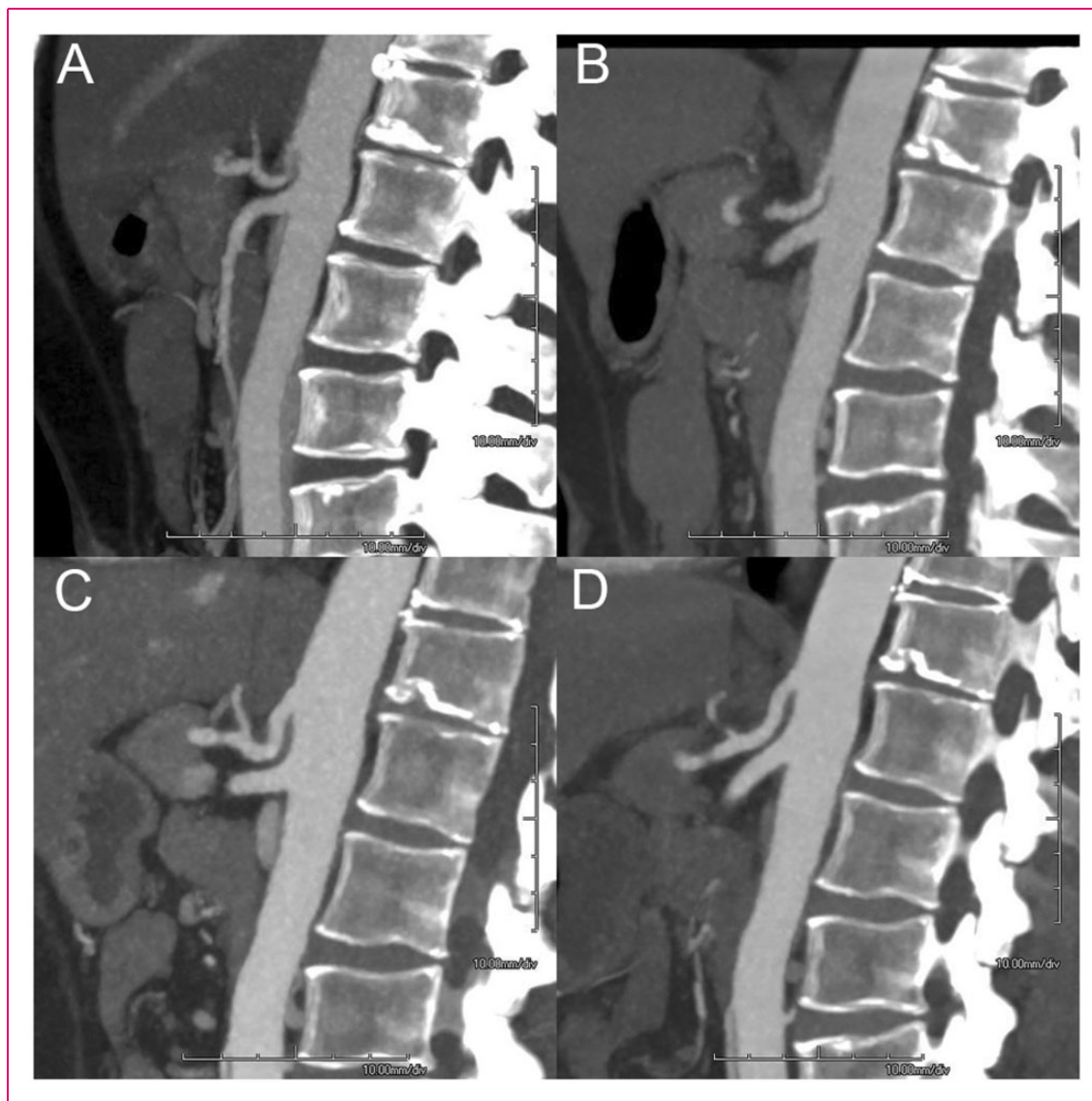

Figure 1. A 48-year-old woman presented with postprandial abdominal pain and 10-kg weight loss. Computed tomography angiography (CTA) showed compression of the celiac artery (CA), with increased compression on expiration (a) and less compression on inspiration (b). Patient was planned for surgical release of CA. After successful release, patient had gained 5 kg in weight and was symptom free. CTA 11 months after surgery showed an open CA on expiration (c) and on inspiration (d).

Table 1. Reported prevalence of characteristics of patients with atherosclerotic CMI versus patients with CMI based on MALS.

	Atherosclerotic CMI ¹²	MALS ¹³⁻¹⁸
Mean age (years)	69	37-54
Female	62%	69-78%
Smoking	66%	33-63%
Hypertension	64%	33%
Hyperlipidemia	41%	13%
CVD	54%	6%

CMI: chronic mesenteric ischemia; CVD: cardiovascular disease; MALS: median arcuate ligament syndrome.

a specificity of 77–90% and a $\geq 70\%$ SMA stenosis with a sensitivity of 72–100% and a specificity of 84–98%.^{3,28} However, DUS is operator dependent, technically challenging and the flow velocities of the evaluated artery could be influenced by respiration, the presence of concomitant stenosis in other mesenteric vessels, and existing stents. Digital subtraction angiography (DSA) is reserved for treatment of occlusive mesenteric artery disease and is replaced by CTA as diagnostic modality. Plain abdominal X-ray has no role in the diagnosis of CMI.

Dynamic imaging is important to detect a CA stenosis caused by MALS because the grade of stenosis

varies with respiration in contrast to atherosclerotic stenosis. CTA, MRA, DUS or DSA during both inspiration and expiration phases are sufficient.

A functional test to prove actual GI ischemia is needed because of the high prevalence of mesenteric stenosis in the asymptomatic general population and the large overlap of symptoms of CMI with many other disorders. Visible light spectroscopy (VLS) performed during upper endoscopy allows measuring of the oxygen saturation of the upper GI mucosa using a fiber-optic catheter passed through the accessory channel of the endoscope connected to the VLS oximeter (T-Stat 303 Microvascular Oximeter; Spectros, Portola Valley, California).²⁹ The sensitivity of VLS measurements for the diagnosis of CMI is 90% and the specificity is 60%.³⁰ The VLS measurements are reproducible in clinical practice with fair to good intraobserver and interobserver reliability.³¹ Tonometry is another functional test that measures luminal partial pressure of carbon dioxide (PCO₂) by a nasogastric and nasojejunal catheter attached to a capnography (Tonocap). Luminal PCO₂ increases during mesenteric ischemia. Exercise tonometry is performed during a bicycle test (sensitivity 78%, specificity 92%¹⁰) and 24-hour tonometry is performed using test meals as provocation (sensitivity 76%, specificity 94%²³). A functional test is not needed in the work-up of the most common CMI suspected patients with typical symptoms and multi-vessel disease (Figure 2). However, especially in the work-up of single-vessel disease a functional test is a prerequisite. It is therefore recommended to refer these patients to a specialized center to undergo functional testing. Research is in progress to develop simple and reliable functional tests that can be widely applied.

Laboratory tests such as leukocytes, D-dimer, lactate and C-reactive protein are not useful for detection of CMI.^{1,32,33} Because CMI is a state of transient ischemia episodes induced by eating, fasted marker levels are presumably not sufficient to indicate CMI. In a study in which several serum markers before and after a meal were determined in patients suspected of CMI, a significant increase of D-dimer was reported in 32 CMI patients after a meal in contrast with 8 patients without CMI.³² Another study in 49 CMI-suspected patients reported a significant increase in intestinal fatty acid-binding protein levels in patients with a positive tonometry result after a meal in contrast with patients with a normal response after a meal.³³ Further research and larger studies are needed to potentially identify a sensitive and specific biomarker for detecting CMI.

In contrast to a diagnosis of acute ischemic colitis, endoscopic assessment of the mucosa by visual appraisal or taking biopsies plays no crucial role in detecting CMI. In CMI patients atrophy of the duodenal mucosa and

non-*Helicobacter pylori*/non-steroidal anti-inflammatory drug gastric or duodenal ulcers are observed in a minority of cases.²⁴ Histological examination of biopsy samples are not discriminative for the diagnosis of CMI.³⁴ Nevertheless, an upper endoscopy remains indicated in CMI-suspected patients to exclude alternative diagnoses, such as peptic ulcer.

Multi-vessel stenoses and classic symptoms will lead to a straightforward diagnosis of CMI. In case of single-vessel disease careful investigation for alternative causes is warranted.¹ Exclusion of other etiologies by imaging of the upper abdomen (DUS/computed tomography (CT)/magnetic resonance (MR)) for gallstones and pancreatitis and upper endoscopy in patients suspected of CMI is important to prevent overtreatment (Figure 2). When a consensus diagnosis of occlusive CMI is established in the multidisciplinary meeting, patients are planned for revascularization therapy. A definitive diagnosis of CMI is proven when technically successful treatment results in durable symptom relief.

Therapy

Revascularization is indicated in patients with occlusive CMI to relieve symptoms, improve quality of life, restore normal weight and improve survival by preventing bowel infarction (acute-on-chronic mesenteric ischemia).¹ The challenge is to select the patient with mesenteric stenosis who will benefit from treatment. Revascularization is accepted in case of symptomatic multi-vessel stenosis (Figure 3). Because the presence of the mesenteric collateral circulation is assumed to prevent single-vessel CMI, revascularization is up for discussion in case of single-vessel stenosis (Figure 1 and Figure 4). However, after careful selection by multidisciplinary consensus and functional assessment persistent symptom relief was reported in 73% of symptomatic patients diagnosed with single-vessel CMI based on a solitary CA or SMA stenosis.⁹

Open surgical revascularization has been the standard therapy modality for years. However, endovascular revascularization is less invasive and has become the therapy of choice in most centers over the past two decades.¹⁻³ The number of endovascular procedures performed for CMI in the USA has increased significantly from 0.6 per million in 2000 to 4.5 per million in 2012 ($p < 0.01$).³⁵

Prospective studies comparing percutaneous transluminal angioplasty (PTA) alone with primary stenting are lacking. However, in parallel to renal artery stenosis and the advantage of stent placement over PTA in this patient group, endovascular therapy for mesenteric stenosis consists of stent placement according to the

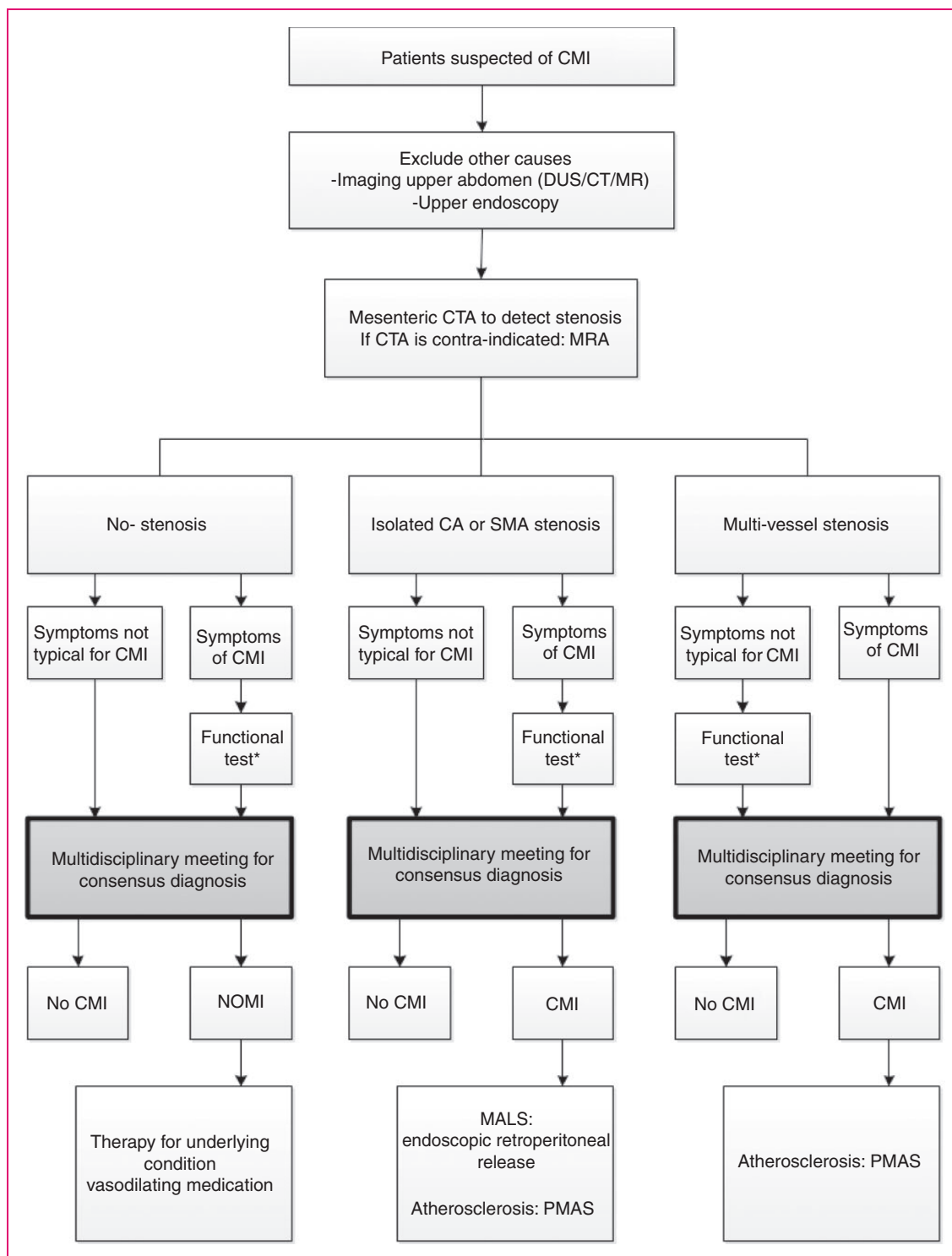


Figure 2. Algorithm for clinical management of chronic mesenteric ischemia.

*Refer for functional test. Suitable functional tests are upper gastrointestinal endoscopy with visible light spectroscopy or gastric-jejunal tonometry (24-hour tonometry or exercise tonometry).

CA: celiac artery; CMI: chronic mesenteric ischemia; CT: computed tomography; CTA: computed tomography angiography; DUS: duplex ultrasound; MR: magnetic resonance; MRA: magnetic resonance angiography; MALS: median arcuate ligament syndrome; NOMI: non-occlusive mesenteric ischemia; PMAS: percutaneous mesenteric artery stenting; SMA: superior mesenteric artery.

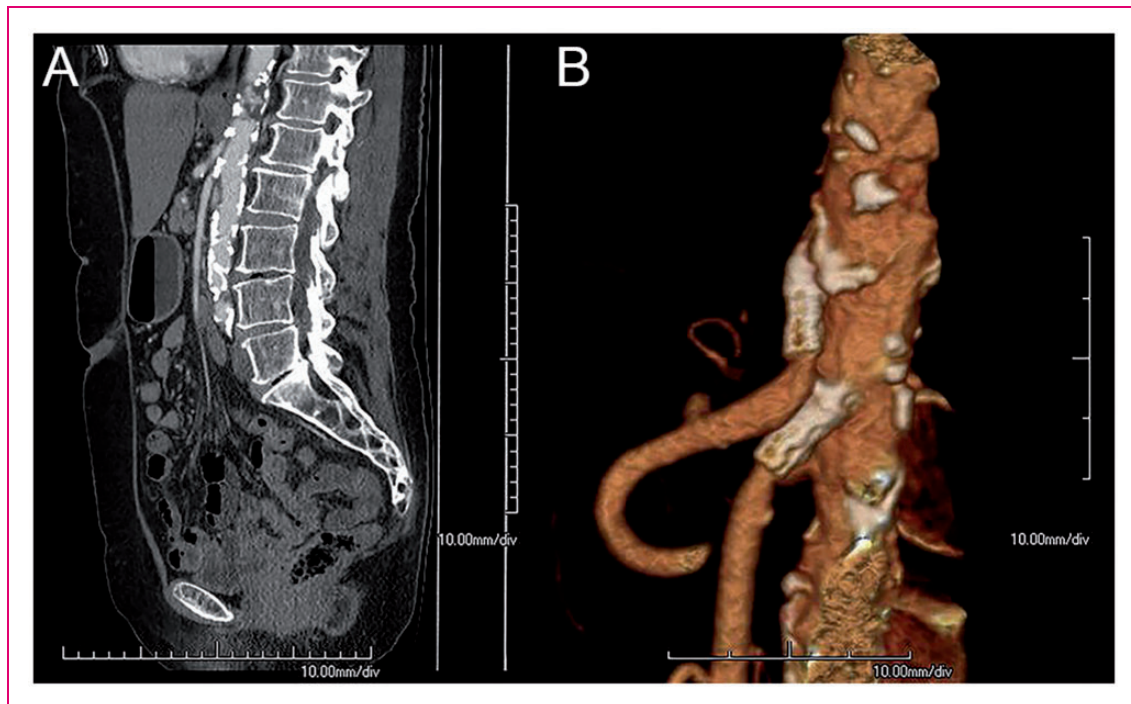


Figure 3. A 69-year-old woman presented with postprandial abdominal pain and 10-kg weight loss over three months. A significant stenosis of the celiac artery (CA) and superior mesenteric artery (SMA) was shown on computed tomography angiography (CTA) (a). A consensus diagnosis of multi-vessel chronic mesenteric ischemia was established and patient was planned for endovascular revascularization. The CA and SMA were successfully stented. CTA 6 months after revascularization showed open stents (b). The patient was free of symptoms and her weight increased by 12 kg.

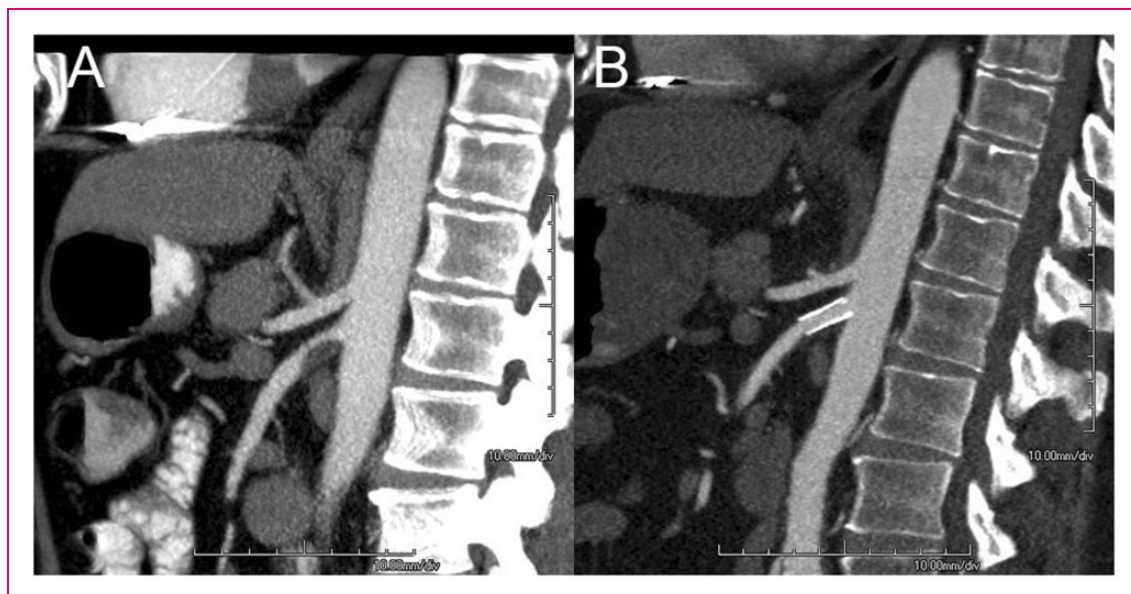


Figure 4. A 50-year-old man presented with postprandial abdominal pain and 13-kg weight loss. Computed tomography angiography (CTA) showed a significant stenosis of the superior mesenteric artery (SMA) and <50% celiac artery stenosis (a). His mucosal saturation levels were decreased as detected by visible light spectroscopy. A consensus diagnosis of single-vessel chronic mesenteric ischemia was established and patient was planned for stent placement of the SMA. CTA 6 months after revascularization showed an open SMA stent (b). The patient was free of symptoms and his weight increased by 7 kg.

ESVS and SIR guidelines.^{1,3} Mesenteric stenoses are usually located at the ostium and are therefore prone to recoil after PTA.^{3,36,37} The endovascular approach is transbrachial or transfemoral, but a transradial approach for percutaneous mesenteric artery stenting (PMAS) is recognized as a safe alternative to the transbrachial approach.³⁸ Bare-metal stents are standard care but retrospective data have reported better primary patency rates when using covered stents.³⁹ Outcome of a Dutch randomized multicenter clinical trial (NCT02428582) is currently awaited to confirm the superiority of covered stents for PMAS.

Open surgical revascularization can be considered if endovascular approach has failed, if endovascular revascularization is technically not possible due to extensive occlusion and calcification and contraindications to radiation or contrast media, or if revascularization is needed in young patients with complex non-atherosclerotic lesions caused by vasculitis or mid-aortic syndrome.¹ Open surgical revascularization can be performed antegrade (from the supraceliac aorta), or retrograde (from the iliac artery), or hybrid with open access to the SMA and retrograde stenting. Autogenously revascularization techniques are first choice but a prosthetic conduit can be used as bypass for one or more vessels as well.

Overall technical success rates of endovascular mesenteric revascularization varied from 85–100% versus technical success rates of surgical revascularization of 97–100%.^{3,6,40} Relative contraindications for endovascular revascularization associated with lower technical success rate and/or increased procedural complications are highly tortuous aorta-iliac arteries, long-segment occlusion, small-diameter distal vessels and heavily calcified stenosis.³ It should be emphasized that ostial occlusion does not exclude PMAS. In a study of 185 CA and SMA vessels treated with PMAS, 21% of the revascularized vessels (9 CA and 30 SMA) were occluded prior to PMAS.⁴¹

Complication rates of surgical revascularization in CMI patients are reported as 13–40%^{24,42} and endovascular complication rates has been reported between 0 and 31% (Table 2).^{2,3} In 4–38% of the cases the complication of the endovascular intervention is access site related, whereby access site hematomas are most reported.^{3,12}

The therapy for MALS consists of surgical release of the MAL, adjacent crus of the diaphragm and removal of the celiac plexus (Figure 4). If stenosis of the CA persists after adequate surgical release, additional bypass surgery or endovascular therapy is performed.⁴³ An endoscopic retroperitoneal release is favorable because this has proved feasible and less invasive with comparable short-term results with the open procedure.¹⁷ PMAS is contraindicated as primary therapy

Table 2. Reported type of complications of mesenteric endovascular revascularization versus mesenteric surgical revascularization.

Complications of endovascular revascularization ^{2,3}	Complications of surgical revascularization ^{24,42}
Hematoma	Bowel resection
Access site dissection	Acute renal failure
Mesenteric dissection	Acute myocardial infarction
Thrombosis	Stroke
Branch perforation	Peripheral vascular disease
Stent dislodgement	Hemorrhage
Distal thromboembolization	Respiratory failure

for MALS, because of the high risk of stent fracture resulting in restenosis.³

Clinical outcome after treatment

Repeated follow-up after therapy for CMI might be considered to detect symptomatic restenosis according to the ESVS guidelines.¹ Routine repeated imaging after therapy may show restenosis, but the benefit of treating asymptomatic restenosis is unknown. Antiplatelet therapy is recommended after revascularization and dual antiplatelet therapy may be considered for 3–12 months.^{1–3}

In-stent stenosis can be seen in 28–36% of endovascular-treated patients within 2 years after PMAS.³ This number is lower after surgical revascularization with 0–25%.^{6,40} Independent predictors of restenosis after mesenteric revascularization are endovascular revascularization, prior mesenteric intervention, female gender and small (<6 mm) SMA diameter.⁴⁴ Severe mesenteric calcification, occlusions, longer lesions and small vessel diameter are associated with an increased risk of distal embolization, restenosis and reinterventions after endovascular revascularization.⁴⁰

Surgical revascularization is associated with a superior long-term patency rate compared to endovascular revascularization (cumulative odds ratio 3.57, 95% confidence interval (CI) 1.82–6.87, $p=0.0002$).⁴⁵ Table 3 shows the 1-year and 5-year primary patency rates and primary assisted patency rates of surgical versus endovascular revascularization.^{3,41,45,46}

A recently published meta-analysis included 100 observational studies to compare endovascular revascularization (10,679 patients) and open surgical revascularization (8047 patients).¹² Risk of in-hospital complications was significantly increased in the open surgical revascularization group (relative risk (RR) 2.19, 95% CI 1.84–2.60). The risk of 3-year recurrence was lower in the patients treated with open surgery than

Table 3. The 1-year and 5-year primary patency rates and primary assisted patency rates of surgical versus endovascular revascularization for CMI.

	Surgical revascularization ^{3,45,46}	Endovascular revascularization ^{3,41}
1-year primary patency rate	91%	58–88%
1-year primary assisted patency rate	96%	90%
5-year primary patency rate	74–90%	45–52%
5-year primary assisted patency rate	96–98%	69–79%

Primary patency rate: uninterrupted vessel patency after initial intervention without repeat intervention.³

Primary assisted patency rate: successful restoration of vessel patency by revascularization therapy of restenosis or a newly occurring arterial stenosis of the previously treated lesion. Primary assisted patency ends with vessel occlusion.³

in the patients treated with endovascular approach (RR 0.47, 95% CI 0.34–0.66). The 3-year survival rate was not significantly different (RR 0.96, 95% CI 0.86–1.07). The ESVS guidelines recommend to offset the superior long-term results of open revascularization against the possible early benefits of endovascular revascularization in the absence of randomized controlled trials.¹

Immediate symptom relief is reported in 90–98% of surgical-treated patients and remains excellent after 5 years with 89–92%.⁶ After endovascular revascularization, immediate symptom relief was reported in 87–95%, symptom relief after 3 years in 61–88%, and in 51% after 5 years.⁶

A retrospective analysis of prospectively collected data (10,920 endovascular revascularized patients versus 4555 surgical revascularized patients) showed that endovascular revascularization is associated with a significantly lower in-hospital mortality rate of 2.4%, shorter length of hospitalization by 10 days, and lower costs of hospitalization with a saving of \$25,000 compared to surgical revascularization.⁴⁷

Conclusion

This review provides an overview on the current clinical management of CMI, which is summarized in an algorithm (Figure 2). Although the exact incidence of CMI is unknown, it is expected that the incidence will increase in the upcoming years due to the aging population and the increasing prevalence of cardiovascular disease in Europe. Cardiovascular disease patients have an increased life expectancy due to the improved diagnostics and better therapeutic opportunities, but these patients are also prone to develop mesenteric atherosclerosis. Patients with CMI present usually with GI symptoms. The diagnostic work-up of the patient suspected of CMI and therapeutic management is multidisciplinary. Early diagnosis is important to timely treat, improve quality of life and to prevent acute-on-chronic mesenteric ischemia.

Author contributions

LJDD: planning and drafting the manuscript; DN: planning and critical revision of the manuscript; ACV, JJK, RHG, HJMV, AM and MJB: critical revision of the manuscript. All authors approved the final draft submitted.

Declaration of conflicting interests

HJMV is a consultant for Medtronic, WL Gore, Endologix and Arsenal AAA. AM has a proctorship for Terumo and Merit Medical. All other authors declared no potential conflicts of interest for the research, authorship, and/or publication of this article.

Ethics approval

Not applicable



Funding

This research received no specific grant from any funding agency in the public, commercial, or not-for-profit sectors.

Informed consent

Not applicable

ORCID iD

Louisa JD van Dijk  <http://orcid.org/0000-0002-6507-5666>
Robert H Geelkerken  <http://orcid.org/0000-0002-6507-5666>

References

1. Bjorck M, Koelemay M, et al. Editor's choice—Management of the diseases of mesenteric arteries and veins: clinical practice guidelines of the European Society of Vascular Surgery (ESVS). *Eur J Vasc Endovasc Surg* 2017; 53: 460–510.
2. Fidelman N, AbuRahma AF, Cash BD, et al. ACR Appropriateness Criteria® radiologic management of mesenteric ischemia. *J Am Coll Radiol* 2017; 14: S266–S271.
3. Pillai AK, Kalva SP, Hsu SL, et al. Quality improvement guidelines for mesenteric angioplasty and stent placement for the treatment of chronic mesenteric ischemia. *J Vasc Interv Radiol* 2018; 29: 642–647.

4. Sana A, Vergouwe Y, van Noord D, et al. Radiological imaging and gastrointestinal tonometry add value in diagnosis of chronic gastrointestinal ischemia. *Clin Gastroenterol Hepatol* 2011; 9: 234–241.
5. Mensink PB, van Petersen AS, Geelkerken RH, et al. Clinical significance of splanchnic artery stenosis. *Br J Surg* 2006; 93: 1377–1382.
6. Clair DG and Beach JM. Mesenteric ischemia. *N Engl J Med* 2016; 374: 959–968.
7. Roobottom CA and Dubbins PA. Significant disease of the celiac and superior mesenteric arteries in asymptomatic patients: predictive value of Doppler sonography. *AJR Am J Roentgenol* 1993; 161: 985–988.
8. van Noord D, Kuipers EJ and Mensink PB. Single vessel abdominal arterial disease. *Best Pract Res Clin Gastroenterol* 2009; 23: 49–60.
9. van Dijk LJD, Moons LMG, van Noord D, et al. Persistent symptom relief after revascularization in patients with single-artery chronic mesenteric ischemia. *J Vasc Surg* 2018; 68: 779–785.
10. Otte JA, Geelkerken RH, Oostveen E, et al. Clinical impact of gastric exercise tonometry on diagnosis and management of chronic gastrointestinal ischemia. *Clin Gastroenterol Hepatol* 2005; 3: 660–666.
11. Kim EN, Lamb K, Relles D, et al. Median arcuate ligament syndrome—review of this rare disease. *JAMA Surg* 2016; 15: 471–477.
12. Alahdab F, Arwani R, Pasha AK, et al. A systematic review and meta-analysis of endovascular versus open surgical revascularization for chronic mesenteric ischemia. *J Vasc Surg* 2018; 67: 1598–1605.
13. Reilly LM, Ammar AD, Stoney RJ, et al. Late results following operative repair for celiac artery compression syndrome. *J Vasc Surg* 1985; 2: 79–91.
14. Mensink PB, van Petersen AS, Kolkman JJ, et al. Gastric exercise tonometry: the key investigation in patients with suspected celiac artery compression syndrome. *J Vasc Surg* 2006; 44: 277–281.
15. Grottemeyer D, Duran M, Iskandar F, et al. Median arcuate ligament syndrome: vascular surgical therapy and follow-up of 18 patients. *Langenbecks Arch Surg* 2009; 394: 1085–1092.
16. Baccari P, Civilini E, Dordoni L, et al. Celiac artery compression syndrome managed by laparoscopy. *J Vasc Surg* 2009; 50: 134–139.
17. van Petersen AS, Vriens BH, Huisman AB, et al. Retroperitoneal endoscopic release in the management of celiac artery compression syndrome. *J Vasc Surg* 2009; 50: 140–147.
18. Roseborough GS. Laparoscopic management of celiac artery compression syndrome. *J Vasc Surg* 2009; 50: 124–133.
19. Kolkman JJ, Bargeman M, Huisman AB, et al. Diagnosis and management of splanchnic ischemia. *World J Gastroenterol* 2008; 14: 7309–7320.
20. Rutjes AW, Reitsma JB, Coomarasamy A, et al. Evaluation of diagnostic tests when there is no gold standard. A review of methods. *Health Technol Assess* 2007; 11: iii, ix–51.
21. Sana A, Moons LM, Hansen BE, et al. Use of visible light spectroscopy to diagnose chronic gastrointestinal ischemia and predict response to treatment. *Clin Gastroenterol Hepatol* 2015; 13: 122–130.e1.
22. van Noord D, Sana A, Moons LM, et al. Combining radiological imaging and gastrointestinal tonometry: a minimal invasive and useful approach for the workup of chronic gastrointestinal ischemia. *Eur J Gastroenterol Hepatol* 2013; 25: 719–725.
23. Mensink PB, Geelkerken RH, Huisman AB, et al. Twenty-four hour tonometry in patients suspected of chronic gastrointestinal ischemia. *Dig Dis Sci* 2008; 53: 133–139.
24. Mensink PB, Moons LM and Kuipers EJ. Chronic gastrointestinal ischaemia: shifting paradigms. *Gut* 2011; 60: 722–737.
25. ter Steege RW, Sloterdijk HS, Geelkerken RH, et al. Splanchnic artery stenosis and abdominal complaints: clinical history is of limited value in detection of gastrointestinal ischemia. *World J Surg* 2012; 36: 793–799.
26. Schaefer PJ, Pfarr J, Trentmann J, et al. Comparison of noninvasive imaging modalities for stenosis grading in mesenteric arteries. *Rofo* 2013; 185: 628–634.
27. Shirkhoda A, Konez O, Shetty AN, et al. Mesenteric circulation: three-dimensional MR angiography with a gadolinium-enhanced multiecho gradient-echo technique. *Radiology* 1997; 202: 257–261.
28. van Dijk LJ, van Petersen AS and Moelker A. Vascular imaging of the mesenteric vasculature. *Best Pract Res Clin Gastroenterol* 2017; 31: 3–14.
29. Benaron DA, Parachikov IH, Cheong WF, et al. Design of a visible-light spectroscopy clinical tissue oximeter. *J Biomed Opt* 2005; 10: 44005.
30. Van Noord D, Sana A, Benaron DA, et al. Endoscopic visible light spectroscopy: a new, minimally invasive technique to diagnose chronic GI ischemia. *Gastrointest Endosc* 2011; 73: 291–298.
31. van Dijk LJD, van der Wel T, van Noord D, et al. Intraobserver and interobserver reliability of visible light spectroscopy during upper gastrointestinal endoscopy. *Expert Rev Med Devices* 2018; 1–6.
32. van Noord D, Mensink PB, de Knegt RJ, et al. Serum markers and intestinal mucosal injury in chronic gastrointestinal ischemia. *Dig Dis Sci* 2011; 56: 506–512.
33. Mensink PB, Hol L, Borghuis-Koertshuis N, et al. Transient postprandial ischemia is associated with increased intestinal fatty acid binding protein in patients with chronic gastrointestinal ischemia. *Eur J Gastroenterol Hepatol* 2009; 21: 278–282.
34. Van Noord D, Biermann K, Moons LM, et al. Histological changes in patients with chronic upper gastrointestinal ischaemia. *Histopathology* 2010; 57: 615–621.
35. Zettervall SL, Lo RC, Soden PA, et al. Trends in treatment and mortality for mesenteric ischemia in the United States from 2000 to 2012. *Ann Vasc Surg* 2017; 42: 111–119.
36. Landis MS, Rajan DK, Simons ME, et al. Percutaneous management of chronic mesenteric ischemia: outcomes

- after intervention. *J Vasc Interv Radiol* 2005; 16: 1319–1325.
37. Sheeran SR, Murphy TP, Khwaja A, et al. Stent placement for treatment of mesenteric artery stenoses or occlusions. *J Vasc Interv Radiol* 1999; 10: 861–867.
 38. Fischman AM, Swinburne NC and Patel RS. A technical guide describing the use of transradial access technique for endovascular interventions. *Tech Vasc Interv Radiol* 2015; 18: 58–65.
 39. Oderich GS, Erdoes LS, Lesar C, et al. Comparison of covered stents versus bare metal stents for treatment of chronic atherosclerotic mesenteric arterial disease. *J Vasc Surg* 2013; 58: 1316–1323.
 40. Oderich GS, Gloviczki P and Bower TC. Open surgical treatment for chronic mesenteric ischemia in the endovascular era: when it is necessary and what is the preferred technique? *Semin Vasc Surg* 2010; 23: 36–46.
 41. Bulut T, Oosterhof-Berkas R, Geelkerken RH, et al. Long-term results of endovascular treatment of atherosclerotic stenoses or occlusions of the coeliac and superior mesenteric artery in patients with mesenteric ischaemia. *Eur J Vasc Endovasc Surg* 2017; 53: 583–590.
 42. Schermerhorn ML, Giles KA, Hamdan AD, et al. Mesenteric revascularization: management and outcomes in the United States, 1988–2006. *J Vasc Surg* 2009; 50: 341–348.e1.
 43. Takach TJ, Livesay JJ, Reul Jr GJ, et al. Celiac compression syndrome: tailored therapy based on intraoperative findings. *J Am Coll Surg* 1996; 183: 606–610.
 44. Oderich GS, Bower TC, Sullivan TM, et al. Open versus endovascular revascularization for chronic mesenteric ischemia: risk-stratified outcomes. *J Vasc Surg* 2009; 49: 1472–1479.e3.
 45. Saedon M, Saratzis A, Karim A, et al. Endovascular versus surgical revascularization for the management of chronic mesenteric ischemia. *Vasc Endovascular Surg* 2015; 49: 37–44.
 46. Gupta PK, Horan SM, Turaga KK, et al. Chronic mesenteric ischemia: endovascular versus open revascularization. *J Endovasc Ther* 2010; 17: 540–549.
 47. Erben Y, Jean RA, Protack CD, et al. Improved mortality in treatment of patients with endovascular interventions for chronic mesenteric ischemia. *J Vasc Surg* 2018; 67: 1805–1812.